

Correction of Frontal Plane Rotation of Sesamoid Apparatus during the Lapidus Procedure: A Novel Approach

Lawrence A. DiDomenico, DPM, FACFAS¹, Ramy Fahim, DPM, AACFAS²,
Jobeth Rollandini, DPM³, Zachary M. Thomas, DPM³

¹ Private Practice, Ankle and Foot Care Centers, Boardman, OH; Section Chief, Department of Podiatry, and Surgeon, Department of Surgery, St. Elizabeth Hospital Medical Center, Youngstown, OH

² Private Practice, Naples, FL

³ Resident, Heritage Valley Health System, Beaver, PA

ARTICLE INFO

Keywords:

bunion
first metatarsal
fluoroscopy
hallux abductovalgus
medial cuneiform
proximal phalanx
sesamoids

ABSTRACT

The Lapidus procedure affords correction of a multitude of first ray pathologic entities. When reconstructing the first ray using the Lapidus procedure, the relocation of the first metatarsal over the sesamoid bones with frontal plane rotation should be considered one of the key components. In the present technical report, we have described a bunion correction with emphasis on sesamoid reduction through indirect frontal plane manipulation. Our technique, borne from applied basic anatomy of the first metatarsophalangeal joint, uses intact soft tissues about the first metatarsophalangeal joint to reduce subluxed or dislocated sesamoids.

© 2014 by the American College of Foot and Ankle Surgeons. All rights reserved.

Many factors contribute to the maintenance of hallux abducto valgus (HAV) correction. Adequate alignment, soft tissue balancing, an atraumatic technique, appropriate fixation techniques, and post-operative protocols all play a role in a successful outcome. We describe a bunion correction with emphasis on sesamoid reduction through indirect frontal plane manipulation (Figs. 1 and 2). Our technique, borne from applied basic anatomy of the first metatarsophalangeal joint (MTPJ), uses these intact soft tissues to reduce subluxed or dislocated sesamoids.

The sesamoid apparatus of the first MTPJ consists of the 2 sesamoids encased in a thick plantar plate and connected by an interosseous ligament. The sesamoids are connected to the first metatarsal head by a medial and lateral metatarsosesamoid ligament and suspensory ligaments and are connected to the first proximal phalanx by medial and lateral sesamophalangeal ligaments. The sesamoid apparatus is also enveloped on a nonarticular plantar surface by the flexor hallucis brevis, transverse and oblique segments of the adductor hallucis, the deep transverse metatarsal ligament, and fibers of the plantar aponeurosis. The tibial and fibular sesamoids are true synovial joints with hyaline cartilage interfaces (1,2). Our surgical rationale was anatomically based. Frontal plane rotation of the first

metatarsal head by manual reduction and ligamentotaxis provided by manipulation of the first proximal phalanx during the modified Lapidus arthrodesis can reliably reduce the sesamoids under the first metatarsal head, leaving the soft tissues intact. This differs from the translational approach, which relies on resection of the lateral soft tissue structures to translate into the transverse plane. Additionally, the standard techniques using typical anteroposterior radiographs provide static views of the deformity and do not foster consideration of the dynamic effects of the soft tissue around the osseous structures.

Surgical Technique

A 4- to 6-cm incision is made over the metatarsal cuneiform joint, and the tarsometatarsal ligaments are resected to expose and prepare the joint. The first tarsal metatarsal joint is destabilized, distracted, and prepared using a combination of a power saw, osteotome, mallet, drills, and picks to ensure good subchondral bone exposure. In contrast to the procedures of the past, dissection of the MTPJ is eliminated, just as is the resection of the medial eminence and the lateral release (Supplemental Video S1).

The reduction maneuver is performed by grasping the hallux and derotating the hallux out of the valgus in a varus direction, which places the nail plate in a neutral position, parallel with the ground. The surgeon then dorsiflexes the first digit while maintaining frontal plane alignment, enabling correction of the sagittal plane. The first metatarsal is put into adduction, and the surgeon's thumb is used to put counterpressure on the first metatarsal head, thus correcting the transverse plane. This allows for the entire hallux, sesamoid, and first

Financial Disclosure: None reported.

Conflict of Interest: None reported.

Address correspondence to: Lawrence A. DiDomenico, DPM, FACFAS, Ankle and Foot Care Centers, 8175 Market Street, Boardman, OH 44512.

E-mail address: ld5353@aol.com (L.A. DiDomenico).


 Video online only at <http://www.jfas.org>

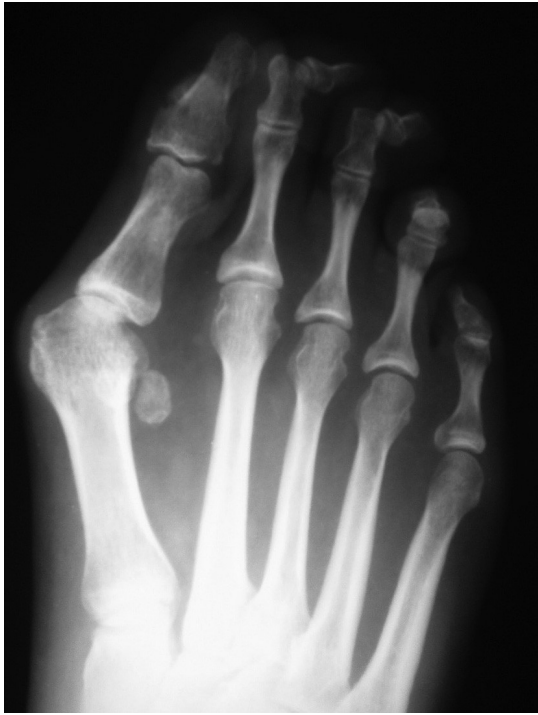

Fig. 1. Preoperative radiograph.

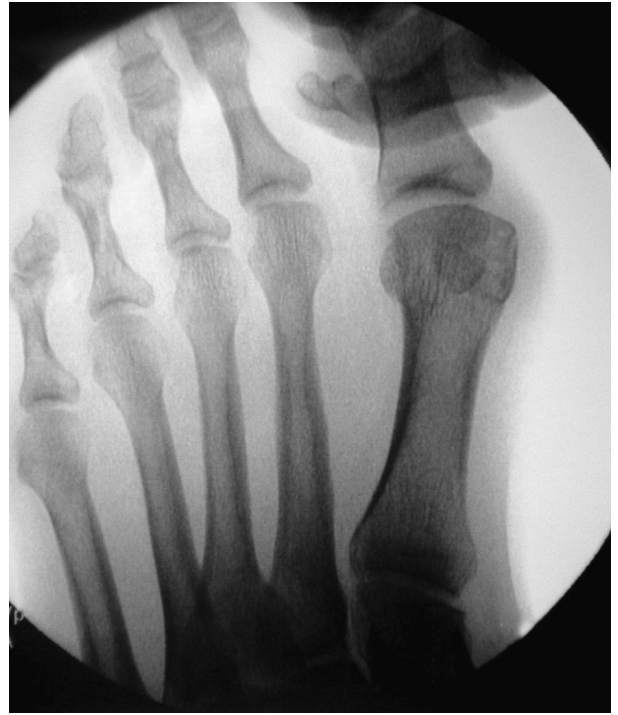

Fig. 3. Intraoperative view after destabilization of the first tarsometatarsal joint and reduction of valgus rotation of the first metatarsophalangeal joint, with the sesamoids rotated into rectus alignment in the frontal plane.

metatarsal complex to be rotated into a neutral position as 1 unit. The sesamoid correction can be observed under fluoroscopy (Figs. 3 and 4). The first tarsal metatarsal joint is pinned with a 2.0 Kirschner wire from dorsally and distally to plantarally and proximally.

If additional frontal plane rotation is needed, the Kirschner wire is backed out. An additional Kirschner wire is placed in the

proximal metaphysis of the first metatarsal, perpendicular to the weightbearing surface, and used as a “joy stick.” The original Kirschner wire is then reintroduced for temporary stabilization from the distal first metatarsal into the cuneiform. A third Kirschner wire is introduced as a second point of fixation from the first metatarsal head into the second while applying abductory pressure to the first

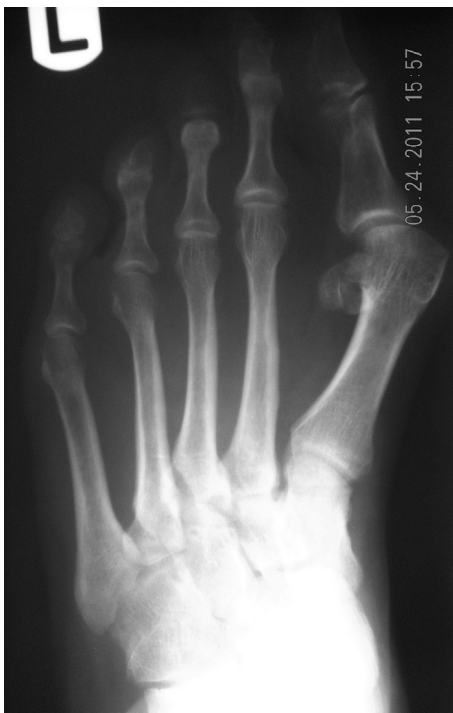

Fig. 2. Preoperative radiograph.

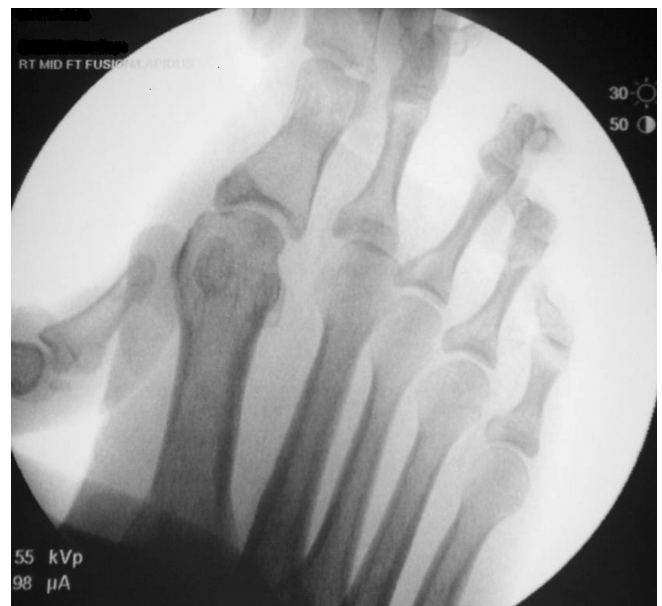

Fig. 4. Intraoperative view after destabilization of the first tarsometatarsal joint and reduction of valgus rotation of the first metatarsophalangeal joint, with the sesamoids rotated into rectus alignment in the frontal plane.

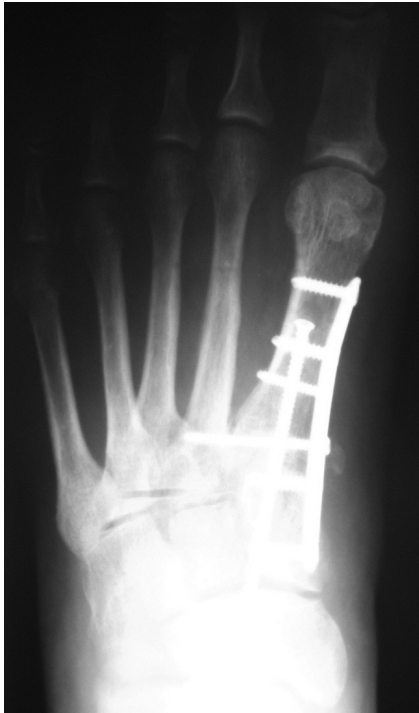

Fig. 5. Postoperative views of the great toe derotated to a neutral position, with complete reduction of the hallux valgus angle and well-aligned sesamoids and metatarsophalangeal joint complex.

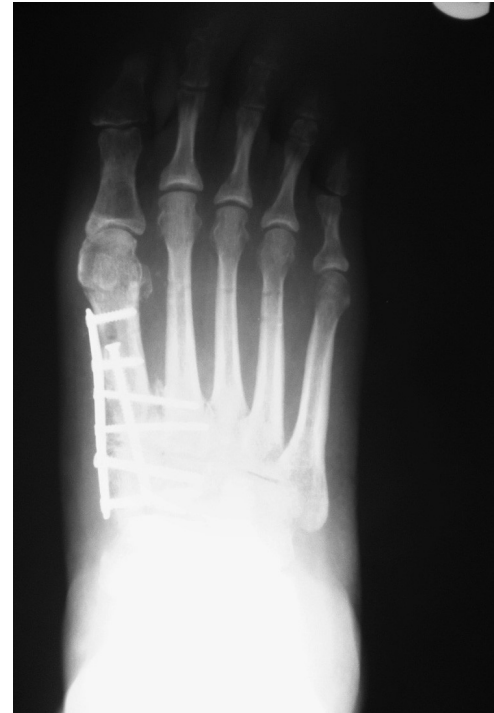

Fig. 6. Postoperative views of the great toe derotated to a neutral position, with complete reduction of the hallux valgus angle and well-aligned sesamoids and metatarsophalangeal joint complex.

metatarsal head. Kirschner wires are used to maintain the correction obtained by these additional maneuvers. Definitive fixation is achieved with a 3.5-mm cortical screw introduced with a lag technique in a “home-run” fashion, as described by Hansen (3). The screw should be as long as possible from anteriorly to posteriorly and should engage the posterior cortex of the medial cuneiform. Finally, a 6-hole combination locking/nonlocking plate is placed to function as a “large washer” in reducing the intermetatarsal angle and maintaining the correction with the locking screws (Figs. 5 and 6).

Discussion

The frontal plane component of HAV correction has recently received some attention. Dayton et al (4) recently stated that frontal plane malalignment is a key component of the HAV deformity and concluded that it must be addressed during correction to provide anatomic alignment of the first MTPJ. We agree with their statements and offer our technique for reliable reduction of an abnormal sesamoid position in HAV. The HAV deformity is essentially a subluxed joint that is malaligned because of instability and hypermobility. Rather than relying on soft tissue releases and capsular repairs, our technique has been based on the mechanics of ligamentotaxis and precise realignment of the bony segments. Resection of the first tarsometatarsal joint enhances the ability to manipulate the first ray into the anatomic position, and stabilization is accomplished. Once the first metatarsal has been derotated and stress is off the soft tissues, the frontal plane will return to the natural anatomic alignment, and the position can be held by fusing the first tarsometatarsal joint.

The normal sesamoid position is a principle factor contributing to normal gait. The results of a 3-dimensional kinematic analysis in a cadaver model demonstrated that the sesamoid apparatus plays a significant role in the biomechanical function of the first ray and that less than optimal realignment of the apparatus can lead to adverse retrograde forces, with the increased possibility of recurrence (5).

Thus, the intraoperative sesamoid position should be evaluated during bunionectomy, regardless of the procedure selected, using either fluoroscopy or direct visualization.

The sesamoids are housed within an intricate network of ligaments, tendons, and capsular structures, all of which function as a

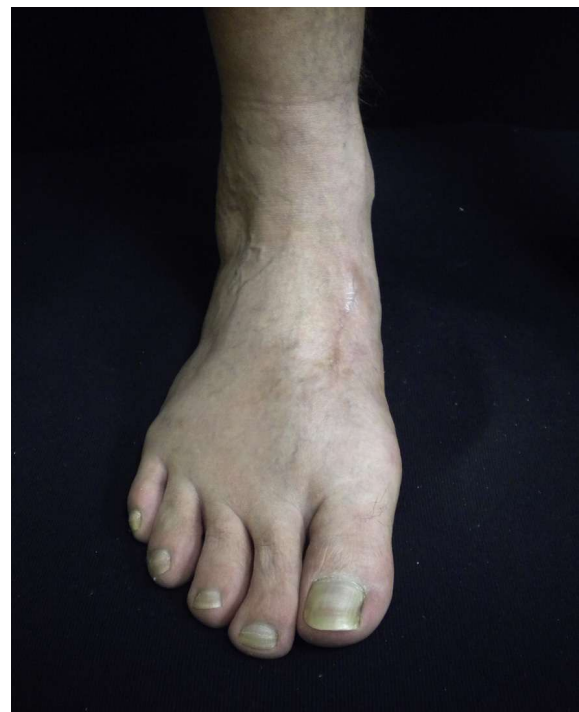

Fig. 7. Clinical photograph of the well-healed foot showing the isolated incision of the tarsometatarsal area.

unit about the first MTPJ (1,6). The traditional methods of sesamoid reduction have involved detaching the restraining structures of the first MTPJ. Various methods have included modifications of McBride's soft tissue release and capsular augmentations, which rely on scar tissue formation to reduce bony deformities (7). Although this has historically been proved to reduce the first metatarsal head under the sesamoid apparatus (8), this technique relies solely on transverse plane motion. Inherently, this will not be an adequate reduction maneuver to reduce the first ray in all 3 planes. Our technique of using the soft tissue-retaining structures of the first MTPJ will also alleviate several postoperative concerns. No scar tissue will be formed along the joint (Fig. 7). The gliding mechanism of the tendon structures about the MTPJ will be maintained. Also, there is no risk of staking the first metatarsal head, and hallux varus is less of a concern, because all the retaining structures about the first MTPJ are intact. Finally, no vascular or nerve concerns exist pertaining to the nutrient artery to the lateral first metatarsal head.

Conclusion

The present report details a technique for using the restraining structures of the first MTPJ rather than severing them. We have seen clinical evidence that the technique we have described is a viable option for correction. From our initial findings, this technique allows the soft tissue to be maintained, affording the patient a less-invasive procedure, with a lower risk of complications. An outcomes study is

currently underway to further validate the effectiveness of our technique.

Supplementary Material

Supplementary material associated with this article can be found in the online version at www.jfas.org (doi:10.1053/j.jfas.2013.12.002).

References

1. Sarrafian SK, Kelikian AS. Osteology. In: *Sarrafian's Anatomy of the Foot and Ankle*, ed 3, edited by AS Kelikian, Lippincott Williams and Wilkins, Philadelphia, 2011.
2. Breslauer C, Cohen M. Effect of proximal articular set angle-correcting osteotomies on the hallux sesamoid apparatus: a cadaveric and radiographic investigation. *J Foot Ankle Surg* 40:366–373, 2001.
3. Hansen ST Jr. First tarsometatarsal joint arthrodesis. In: *Functional Reconstruction of the Foot and Ankle*, pp. 335–340, edited by ST Hansen, Lippincott Williams & Wilkins, Philadelphia, 2000.
4. Dayton P, Feilmeier M, Kauwe M, Hirschi J. Relationship of frontal plane rotation of first metatarsal to proximal articular set angle and hallux alignment in patients undergoing tarsometatarsal arthrodesis for hallux abducto valgus: a case series and critical review of the literature. *J Foot Ankle Surg* 52:348–354, 2013.
5. Rush SM, Christensen JC, Johnson CH. Biomechanics of the first ray. Part II: metatarsus primus varus as a cause of hypermobility. A three-dimensional kinematic analysis in a cadaver model. *J Foot Ankle Surg* 39:68–77, 2000.
6. Gerber M, Roberto PD. Sesamoids. In: *Hallux Valgus and Forefoot Surgery*, pp. 153–162, edited by VJ Hetherington, OCPM, Cleveland, 2000.
7. McBride ED. A conservative option for bunions. *J Bone Joint Surg* 10:735–739, 1928.
8. Judge MS, LaPointe S, Yu GV, Shook JE, Taylor RP. The effect of hallux abducto valgus surgery on the sesamoid apparatus position. *J Am Podiatr Med Assoc* 89:551–559, 1999.