

Use of a Modified Cardiopulmonary Bypass Circuit for Suction Embolectomy with the AngioVac Device

Cara M. Michelson, MPS, CCP; Cornelius M. Dyke, MD; Douglas J. Wick, MPS, CCP;
Rory Guenther, BA; Dylan Dangerfield, BA; Matthew E. Wiisanen, MD

University of North Dakota School of Medicine and Health Sciences, Sanford Health Fargo, Fargo, North Dakota

Abstract: The AngioVac suction cannula and circuit were designed for the percutaneous removal of soft thrombus and emboli in procedures requiring extracorporeal circulatory support. We describe a modification of the AngioVac suction catheter and cardiopulmonary bypass (CPB) circuit to effectively remove thrombus while maintaining the ability to rapidly initiate full CPBs during a medical crisis. This article will discuss the design

concepts of the modified circuit as well as procedural protocols and considerations. The design modifications of incorporating an oxygenator, reservoir, and bridge allow for an increased flexibility that allows adaption to veno-venous extracorporeal membrane oxygenation or full CPB support when required for oxygenation or hemodynamic support. **Keywords:** suction embolectomy, cardiopulmonary bypass, AngioVac. *J Extra Corpor Technol. 2017;49:299–303*

The AngioVac suction catheter and perfusion system (AngioDynamics, Inc., Latham, NY) is indicated for the removal of intravascular fresh thrombus or embolus. The most common indication for use is the treatment of acute venous thromboembolic disease, although other reported applications include the removal of right atrial tumors, foreign bodies, and right-sided cardiac valve vegetations (1–10). Standard surgical therapy for thrombectomy or valvular debridement requires sternotomy and full cardiopulmonary bypass (CPB). Less invasive techniques may be advantageous in critically ill or unstable patients in whom a surgical approach may be associated with significant morbidity or mortality (1,7).

The AngioVac cannula and perfusion system is a relatively new method first used for percutaneous thrombectomy in 2009. Currently, approved by the Food and Drug Administration for the removal of soft thrombi and emboli, the AngioVac device does not require fragmentation of thrombi, thus reducing the risk of embolization (11). The removal of whole intact thrombus and soft tissue vegetations is accomplished by a large bore aspiration cannula attached to an extracorporeal circuit with filter and

subsequent venous reinfusion catheter (2,12). The traditional AngioVac circuit does not include a reservoir or oxygenator. We have adapted the AngioVac system to include a modified CPB circuit to allow for simple and rapid conversion to either veno-venous ECMO or full CPB, which may be particularly beneficial for patients with venous thromboembolic disease. This article describes our modifications of the circuit and initial clinical experience.

PERFUSION CONCEPTS AND CIRCUIT MODIFICATIONS

Circuit Development

Our prototype for a modified CPB circuit was set up on the Medtronic Performer (Medtronic Inc., Minneapolis, MN) CPB bypass machine. The prototype included a traditional CPB circuit with Affinity Fusion cardiotomy and an oxygenator (Medtronic Inc.) with an integrated arterial filter and a Medtronic Affinity centrifugal pump. The modified CPB differs from the conventional AngioVac circuit (AngioDynamics, Inc) in that it uses a full CPB circuit on the Medtronic Performer bypass machine with reservoir and oxygenator rather than a standalone centrifugal pump. The traditional CPB circuit was modified by adding a 3/8th inch piece of polyvinylchloride tubing from the venous line just before the centrifugal pump. This additional tubing functions as a bypass line around the reservoir. Within this piece of tubing, a bubble trap was incorporated to catch any thrombus suctioned from the

Received for publication February 5, 2017; accepted July 16, 2017.
Address correspondence to: Cornelius M. Dyke, MD, Associate Professor, Department of Surgery, University of North Dakota School of Medicine and Health Sciences, Sanford Health Fargo, 801 Broadway North, Fargo, ND 58103. E-mail: cornelius.dyke@sanfordhealth.org

The senior author has stated that the authors have reported no material, financial, or other relationship with any healthcare-related business or other entity whose products or services are discussed in this paper.

AngioVac cannula. A second modification included a bypass line around the bubble trap for the easy addition of a second bubble trap in the event the first bubble trap fills with thrombus. We also incorporated a bridge from the patient inflow line to the venous line. This bridge is used for priming the circuit and allows the perfusionist to pump to the field for a wet connection at the AngioVac cannula and reinfusion cannula.

The circuit has a 1/2 inch venous line and 3/8 inch inflow line. The durometer of venous line had to be increased from INT 68 on the traditional CPB circuit to INT 71 on the modified circuit because of high suction values causing tubing collapse. A 1/2 inch venous line was chosen over a 3/8th inch line for the modified circuit to prevent the need for high vacuum in the instance where full CPB support is required. The tubing durometer was tested in a laboratory setting using .9% sodium chloride by increasing the flow up to 7000 mL/min and observing no tubing collapse or change in venous pressure. No additional vacuum was applied to the closed circuit mimicking the clinical procedure in which suction is solely generated from the centrifugal head. The 3/8-inch patient inflow line is able to connect directly to the 19 French reinfusion cannula. There is a two-step process to connect the 1/2 inch pump tubing to the AngioVac cannula. First, a 1/2 × 3/8 straight connector is attached at the sterile field to the 1/2 inch venous line. Next, the toughy port with 3/8 inch tubing must be cut from the AngioVac circuit and attached to the 1/2 × 3/8 straight connector. The venous line is now able to connect to the AngioVac cannula. The complete circuit setup is shown in Figure 1.

The modified CPB differs from the conventional AngioVac circuit in that it uses a full CPB circuit on the Medtronic Performer bypass machine with reservoir and oxygenator rather than a standalone centrifugal pump.

Procedural Considerations

The circuit is primed using 1.5 L of Isolyte multi-electrolyte solution (Braun Medical Inc., Bethlehem, PA) through the bridge until the lines are passed off from the sterile field and patient inflow and venous lines are connected. At this point, the A-V loop can be primed, clamped, and cut at the sterile field. After the circuit has been primed, all shunts circulating back to the reservoir must be closed including the manifold, hemoconcentrator, and the oxygenator purge line to prevent blood from entering the reservoir once flow is initiated. The hemoconcentrator and ancillary lines are not depicted in the diagram as they are not used during the AngioVac procedure. In addition, there should be a clamp placed between the venous line and the bubble trap.

Before initiation of suction, anticoagulation with unfractionated heparin is used to achieve a target activated clotting time (ACT) greater than 480 seconds higher than the recommended ACT of 250 with the traditional

AngioVac circuit due to the addition of an inline oxygenator. Once the ACT is confirmed, antegrade autologous priming can be accomplished by draining the venous line back to the reservoir and allowing the venous line to passively fill with patient blood. At this point, the reservoir should be completely clamped out of the circuit, and the bridge should be clamped. The AngioVac suction is initiated by the perfusionist removing the clamp from the inflow and venous line and opening the clamp to the bubble trap. This clamp placement provides a closed circuit allowing the centrifugal pump to provide the necessary suction for thrombus removal without the use of additional vacuum. Blood should be flowing from the AngioVac catheter, through the bubble trap via the venous line, through the centrifugal pump to the oxygenator, and then back into the patient via the reinfusion cannula. The perfusionist can manipulate the flow to increase or decrease suction with the direction of the surgeon or cardiologist. During some AngioVac procedures, the position of the suction catheter may need to be manipulated. Rather than turning off the pump, the inflow and venous lines can be clamped and the bridge can be opened to recirculate through the circuit to prevent stagnant blood. Once the thrombus has been sufficiently removed, the perfusionist will clamp the inflow and venous lines. Using the volume in the reservoir, the perfusionist can displace the blood volume in the patient inflow line and venous line to prevent blood loss to the circuit.

Emergent Conversion to Venovenous ECMO or CPB

A great advantage to using a modified bypass circuit with the AngioVac cannula is the potential to convert to venovenous extracorporeal membrane oxygenation (ECMO) or full CPB support using the same circuit, depending on the clinical situation. The in-line oxygenator in the modified CPB circuit allows for the treatment of patients with severe hypoxia with venovenous ECMO through the established internal jugular and femoral venous catheters. This ECMO technique is for temporary extracorporeal oxygenation support. If long-term ECMO support is desired the patient will need to be transferred to a dedicated ECMO circuit. If full CPB is needed because of clot migration or other clinical emergency causing hemodynamic instability, the 19 French reinfusion cannula may be moved from the femoral vein to the femoral artery. Initiating full bypass support is accomplished by temporarily stopping the flow to the patient, clamping out the bubble trap, and opening the clamps surrounding the reservoir.

CLINICAL EXPERIENCE

Technical Considerations

All cases where the AngioVac system was used in our hospital are included in this report (April 2014 to February

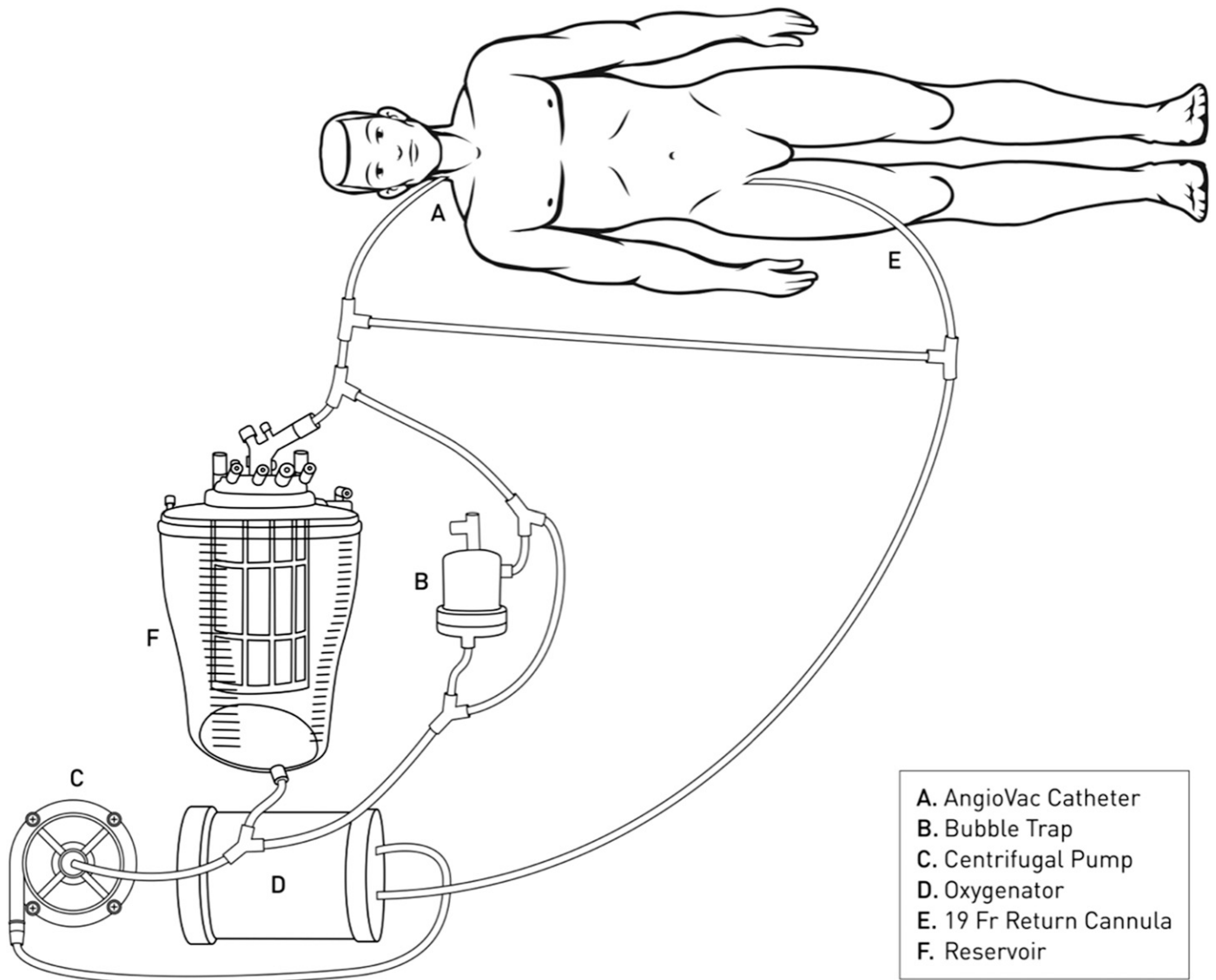


Figure 1. Modified circuit for suction embolectomy.

2017). A total of seventeen patients were treated. Procedures were performed under general anesthesia in the hybrid catheterization laboratory by the Heart Team, which included personnel from interventional cardiology, cardiac surgery, and cardiac perfusion. Fluoroscopy and transesophageal echocardiographic guidance were used in all cases. Anticoagulation with unfractionated heparin was used to achieve a target ACT of >250 seconds or >480 seconds for full CPB. Percutaneous access was achieved in both common femoral veins and the right internal jugular vein. Continuous arterial pressure was monitored with a radial artery catheter. The aspiration venous access sites (either the right internal jugular vein or the right common femoral vein) were successively dilated

to allow a 26-F Gore DrySeal sheath (W.L. Gore & Associates, Flagstaff, AZ) over a .035-inch Amplatz (Boston Scientific, Marlborough, MA) or .035-inch Lunderquist (Cook, Inc., Bloomington, IN) guide wire. Before insertion through the DrySeal sheath, the 19-F AngioVac cannula was shaped using a heat gun to create a J-shaped tip to enhance steerability. The cannula was inserted through the sheath over the Amplatz or Lunderquist wire to the area of pathology under fluoroscopic and transesophageal echocardiography guidance. Once the AngioVac circuit was established, flow through the extracorporeal circuit was initiated and slowly increased to a maximum rate of 4 L/min while actively monitoring hemodynamics. Once the flow was established,

Table 1. Procedural outcomes.

	Total (n = 17)	Conventional Circuit (n = 11)	Modified Circuit (n = 6)
Average pre-op hemoglobin (mg/dL)	10.67 ± 3.04	11.61 ± 3.26	8.95 ± 1.65
Average post-op hemoglobin (mg/dL)	9.50 ± 2.59	10.44 ± 2.53	7.78 ± 1.78
Average change in hemoglobin	-1.17 ± 2.02	-1.17 ± 1.48	-1.17 ± 2.94
Pre-op transfusion	53%		
Intraoperative transfusion	47%		
Post-op transfusion	35%		
Average fluoroscopy time (min)	36 ± 26		
Average perfusion time (min)	58 ± 64		

the suction cannula was oriented toward the area of vegetation or thrombus. Blood and foreign material were captured with the suction catheter and returned through the venovenous nonoxygenating bypass circuit, allowing for filtration of blood before return into the venous circulation through the reinfusion cannula (13). As in any case, hemodynamic stability during the angiovac procedure requires collaboration with the anesthesia team and perfusion team. Volume shifts are usually minimal as little volume is lost during sheath placement. Vasoactive medications and volume supplementation while on the angiovac system are given and managed by the anesthesia staff.

Patient Outcomes

Sixteen patients underwent vegetation debulking or thrombectomy using the AngioVac catheter system, of which twelve were performed on the conventional AngioVac circuit and six on the modified CPB circuit. Indications for use included the presence of atrial or caval thrombus (6/16, 37.5%) and tricuspid and pulmonary valve vegetations (10/16, 62.5%). Technical success was achieved in 15/16 patients, as defined by the uneventful placement of cannulae and successful use of the AngioVac suction catheter with the capture of clot or vegetative material within the suction canister filter and uncomplicated decannulation. In one patient with pulmonary artery clot, hemodynamic instability occurred while attempting to maneuver the catheter into the right ventricular outflow tract, resulting in perforation and injury to the right ventricular free wall. In this patient, conversion to ECMO allowed stabilization while median sternotomy could be performed for definitive repair. There were no periprocedural deaths. Patient outcomes and postoperative complications are summarized in Table 1. The use of the modified CPB circuit with oxygenator did not alter the change in hemoglobin when compared with the conventional AngioVac circuit. The average length of stay was 12 ± 11 days with no in-hospital or 30-day mortality.

SUMMARY

The AngioVac suction cannula and extracorporeal circuit allow for a less invasive technique for the removal of soft tissue thrombus and embolus compared with surgical approach. Through our experience using the AngioVac suction catheter on 16 patients, we found increased safety and flexibility by incorporating a modified CPB circuit to our procedural protocol. With the addition of a cardiotomy, oxygenator, and bridge to the conventional AngioVac extracorporeal circuit, we have the ability to rapidly initiate veno-venous ECMO or full CPB support. It is unnecessary to have a second circuit available to convert to oxygenated support, thus increasing simplicity during the rapid onset of hemodynamic instability.

REFERENCES

- Hosoba S, Mori M, Furtado AD, et al. Extraction of right-sided vegetation with the use of an aspiration catheter system. *Innovations (Phila)*. 2015;10:357-9.
- Donaldson CW, Baker JN, Narayan RL, et al. Thrombectomy using suction filtration and veno-venous bypass: Single center experience with a novel device. *Catheter Cardiovasc Interv*. 2015;86:E81-7.
- Grimm JC, Parsee AM, Brinker JA, et al. Utilization of AngioVac and snare for eradication of a mobile right atrial thrombus. *Ann Thorac Surg*. 2015;99:698-700.
- Moriarty JM, Al-Hakim R, Bansal A, et al. Removal of caval and right atrial thrombi and masses using the AngioVac device: Initial operative experience. *J Vasc Interv Radiol*. 2016;27:1584-91.
- Smith SJ, Behrens G, Sewall LE, et al. Vacuum-assisted thrombectomy device (AngioVac) in the management of symptomatic ilio caval thrombosis. *J Vasc Interv Radiol*. 2014;25:425-30.
- Nickel B, McClure T, Moriarty J. A novel technique for endovascular removal of large volume right atrial tumor thrombus. *Cardiovasc Intervent Radiol*. 2015;38:1021-4.
- Pasha AK, Elder MD, Khurram D, et al. Successful management of acute massive pulmonary embolism using AngioVac suction catheter technique in a hemodynamically unstable patient. *Cardiovasc Revasc Med*. 2014;15:240-3.
- Al-Hakim R, Patel K, Moriarty J. AngioVac aspiration for paradoxical emboli protection through a fenestrated fontan during central venous thrombus manipulation. *Cardiovasc Intervent Radiol*. 2015;38:752-4.
- Makdisi G, Casciani T, Wozniak TC, et al. A successful percutaneous mechanical vegetation debulking used as a bridge to surgery in acute tricuspid valve endocarditis. *J Thorac Dis*. 2016;8:E137-9.

10. Divekar AA, Scholz T, Fernandez JD. Novel percutaneous transcatheter intervention for refractory active endocarditis as a bridge to surgery-AngioVac aspiration system. *Catheter Cardiovasc Interv.* 2013;81:1008–12.
11. Worku B, Blake K, Gulkarov I, et al. Percutaneous removal of filter-induced ilio caval thrombus using the AngioVac device. *Innovations.* 2015;10:212–4.
12. Scher D, Nghiem W, Aziz S, et al. Endometrial stromal sarcoma metastatic from the uterus to the inferior vena cava and right atrium. *Tex Heart Inst J.* 2015;42:558–60.
13. Todoran TM, Sobieszczyk PS, Levy MS, et al. Percutaneous extraction of right atrial mass using the AngioVac aspiration system. *J Vasc Interv Radiol.* 2011;22:1345–7.