

IVUS-based Assessment of 3D Morphology and Virtual Histology: Prediction of Atherosclerotic Plaque Status and Changes

Milan Sonka, *Fellow IEEE*, Richard W. Downe, *Student Member IEEE*, Justin W. Garvin,
John Lopez, Tomas Kovarnik, Andreas Wahle, *Senior Member IEEE*

Abstract—Comprehensive analysis of coronary morphology, plaque composition, hemodynamics, and systemic cardiovascular biomarkers is hypothesized to allow prediction of plaque development. We report the status of a comprehensive project, in which baseline and follow-up intravascular ultrasound imaging of coronary arteries during routine coronary interventions serve as a source of quantitative data for development of a predictive classifier for determining plaque progression over the course of a year from baseline data.

I. INTRODUCTION

The coronary atherosclerotic process starts early and advances throughout adult life when rupture of vulnerable plaque or occlusive coronary disease causes acute coronary syndromes or chronic angina with complications including myocardial infarction and sudden death. Studies of the relationships between local vessel morphology, plaque composition, blood flow dynamics including endothelial shear stress, biomarkers, and atherosclerotic plaque progression at 12 months may offer insights in the natural course of plaque development and consequently allow predictions about atherosclerotic disease progression from initial imaging and coronary vessel modeling. We hypothesize that baseline imaging and analysis of coronary morphology and function in 3-D will provide sufficient information to serve as an input to a predictive classifier identifying locations on the coronary wall that are likely to demonstrate plaque progression in the future.

Emerging data on the development and progression of coronary atherosclerosis reveals a complex process where genetic factors interact with inflammatory, thrombotic, and humoral processes in addition to biomechanical forces within the vasculature. The relative contribution of these processes to atherosclerosis development is not clear, and in-vivo clinical data are sparse. Nevertheless, logical relationships can be identified between the current and future status of the atherosclerotic disease.

This paper reports an ongoing study, in which serial in-vivo intravascular (IVUS) imaging of patients with coronary artery disease is expected to provide insights into

This work was supported, in part, by the U.S. National Institutes of Health, National Heart, Lung, and Blood Institute, R01 HL-63373.

M. Sonka, R. Downe, and A. Wahle are with the Iowa Institute for Biomedical Imaging, The University of Iowa, Iowa City IA, USA. Email: milan-sonka@uiowa.edu

J. Garvin is with the IIHR - Hydroscience and Engineering, The University of Iowa, Iowa City IA, USA.

J. Lopez is with the Loyola University, Chicago IL, USA.

T. Kovarnik is with the Charles University, Prague, Czech Republic.

the temporal effects of vessel morphology, plaque composition, hemodynamics, and systemic inflammatory and other vascular biomarkers on local atherosclerosis progression, thus allowing the prediction of changes in the burden, location and extent of atherosclerosis. It is expected that assessment of such complex multi-factorial properties will allow predictions about the subsequent development of local atherosclerosis.

The development of atherosclerotic vascular disease is a complex process involving lipid accumulation, plaque rupture and erosion, thrombosis, healing, and vessel adaptation. Factors in this process include autocrine–paracrine interactions, leukocyte and macrophage interactions, inflammatory pathways, intercellular communications, lipid effects, and the thrombotic milieu. Recent work also points to an important role for local hemodynamic stresses in the extent of and predilection for atherosclerosis formation.

Previous efforts to model atherosclerosis development by clinical angiographic or intravascular ultrasound studies have not involved an accurate three-dimensional imaging system, where an understanding of the hemodynamic conditions present within the vessel can be incorporated. In addition, prior efforts have been unable to involve follow-up studies over time, to monitor temporal changes in vessel architecture and plaque burden as a consequence of an initial hemodynamic milieu. Finally, there is no prior data linking systemic inflammatory markers or other biomarkers which reflect the local vascular milieu to sophisticated in-vivo IVUS imaging where complex plaque morphology can also be identified.

The fusion of IVUS with X-ray angiography as performed by us [1], [2], [3] and others (e.g., the Thoraxcenter in Rotterdam or the Cleveland Clinic Foundation) builds a strong basis for both hemodynamic and morphologic analyses in the true vessel geometry. The extension of these methods into analyses in the moving vessel consequently may further allow a more accurate modeling of the 4-D vascular hemodynamics, consideration of true spatio-temporal parameters such as twisting of the vessel over the cardiac cycle [4], and to correlate the moving vessel geometry with local shear stress patterns and plaque development.

Virtual Histology (VH), utilizes the underlying radio-frequency data of IVUS imaging to identify different plaque types: fibrous, fibro-fatty, necrotic core, and dense calcium plaque. This improves substantially the amount of information that can be obtained from IVUS imaging. In brief, a spectral analysis is performed on the backscattered radio-frequency signal. The sampling frequency of this signal is

Fig. 1. The top part of this flow chart shows the parallel paths of processing the biplane angiography and IVUS data, which lead to the fused 3-D / 4-D *plain model*, consisting of the lumen and adventitia contours oriented relative to the IVUS catheter. After tetrahedral meshing, this model is suitable for hemodynamic analyses. Following resampling relative to the vessel centerline, morphologic analyses are performed. The quantitative data *annotate* the resampled contour model, which then can be used for visualization and further analyses.

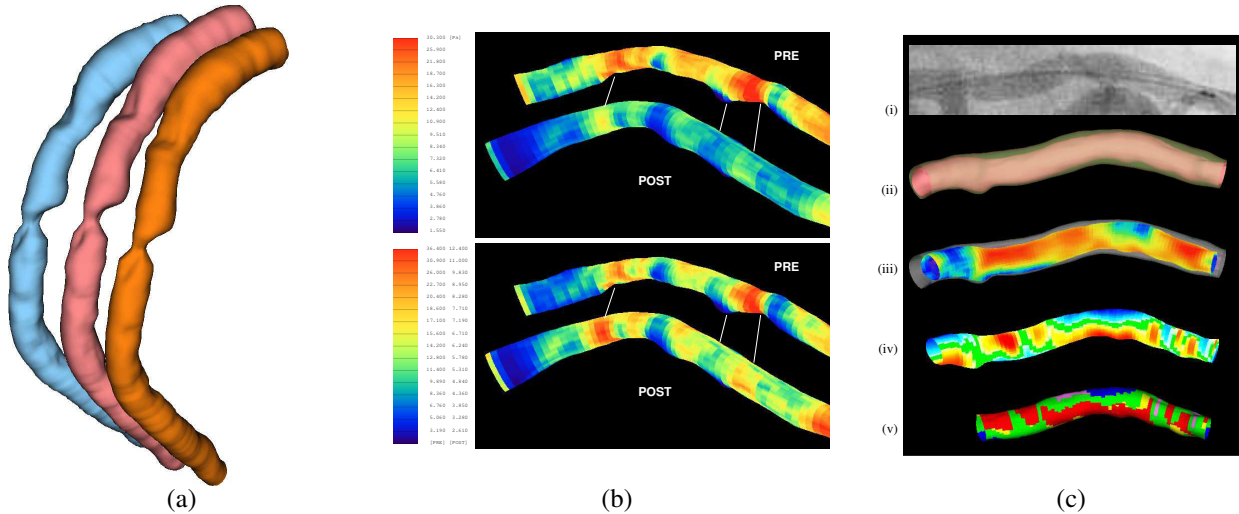
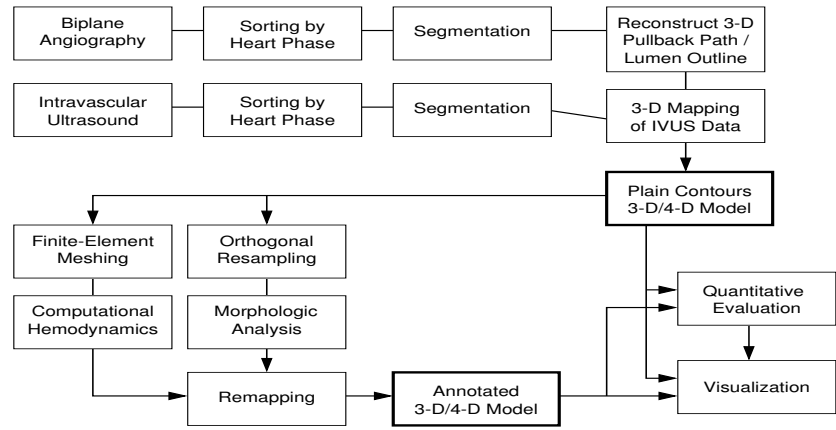


Fig. 2. Quantitative visualization. (a) 3-D lumen contours of three out of six reconstructed heart phases of a right coronary artery. (b) Lumen surfaces of a left anterior descending (LAD) artery pre and post balloon intervention, where the upper panel is using the same colormap for both pullbacks and is thus reflecting different physiologic parameters prior and after the intervention, whereas the lower panel allows a more local comparison by individually optimized colormaps. (c) Correlation between plaque thickness and curvature: (i) RAO (right anterior oblique) view angiogram of an LAD artery, (ii) lumen and adventitia borders from fusion, (iii) plaque-thickness annotation, (iv) curvature-index annotation, (v) after classification into regions.

about $3\times$ as high as the transducer frequency (e.g., 100 MHz for a 30 MHz catheter). The data are fed into a classifier based on autoregressive analysis. The classifier was trained on in-situ image data for which histology was available as the gold standard.

II. QUANTITATIVE ANALYSIS OF CORONARY WALL MORPHOLOGY AND TISSUE COMPOSITION

We have developed a method for the geometrically accurate representation of coronary arterial morphology and hemodynamics in vivo (vessel lumen, plaque, wall morphology, and wall shear stress) via fusion of image data from biplane coronary angiography and intravascular ultrasound in 3-D. The flowchart outlining the main system blocks is given in Fig. 1. The developed data fusion system treats all necessary steps in a unified manner, including data import, angiography and IVUS segmentation, multimodality fusion, and calculation of quantitative indices. A database system for data and analysis-result handling, control, and maintenance was developed to allow comprehensive tracking

of all acquired and computed data.

We have also developed a comprehensive interactive visualization tool allowing the display and manipulation of results from reconstruction, fusion, and quantifications in 3-D. Among other things, it conveys vessel geometry, plaque distribution, hemodynamic parameters, and the outcome of intracoronary interventions. Fig. 2 provides several examples of 3-D visualizations routinely available to the users of the Fusion system, also providing a virtual-angiography mode. To facilitate interaction, the user can navigate within the vessel using a Virtual Reality Modeling Language (VRML) encoded control panel that is available on demand and that can be hidden when not needed. The entire system is modular, with the overall functionality achieved by independent single-purpose modules that were separately tested and then integrated into a comprehensive fusion system.

Many meaningful measures of quantitative plaque morphology can be derived from the geometrically correct 3-D representation of the vessel. Our quantitative indices are based on the identified lumen/plaque and media/adventitia

interfaces in 3-D. Most of the computed quantitative indices are those generally accepted as reflecting local vascular disease severity. The indices are divided in four separate groups: 1) local (elemental) indices; 2) cross-sectional indices; 3) regional (tile) indices; and 4) segmental indices.

Table I provides a comprehensive overview of the utilized indices. While calculation of morphologic indices is easy to understand, tissue characterization may need a brief description. Tissue characterization indices are obtained from virtual histology (Volcano Therapeutics, Inc.), which classifies each point in the image data between the luminal and adventitial borders into one of 4 tissue classes: fibrous, fibro-fatty, necrotic core, and dense calcium. Each data point has its location information associated with it maintaining a one-to-one correspondence between the tissue characterization and IVUS image data. Since the tissue classification is only valid for the plaque region, lumen-intima and media-adventitia segmentation must be available (Fig. 3). Due to the locational registration between the tissue classification and image data, our segmentation method is used to identify the plaque region. Consequently, each point in the plaque region will have a plaque class associated with it. To allow usage of the morphology and plaque composition indices given in Table I for prediction of plaque progression, these indices are registered with the geometrically correct model of the vessel in 3-D considering branches and hemodynamics (Fig. 4).

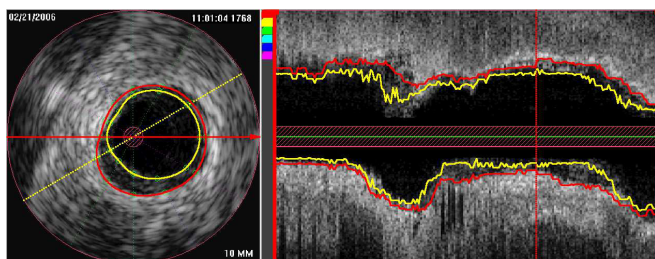


Fig. 3. Automated segmentation of intravascular ultrasound data in 3-D.

III. PREDICTING TEMPORAL CHANGES IN ATHEROSCLEROTIC PLAQUE IN VIVO FROM MULTIFACTORIAL COMPUTATIONAL ASSESSMENT OF 3-D CORONARY GEOMETRY, HEMODYNAMICS, PLAQUE MORPHOLOGY AND COMPOSITION, WITH THE CONCOMITANT DETERMINATION OF SYSTEMIC ATHEROSCLEROSIS-RELATED BIOMARKERS.

The quantitative indices described above allow to train a classification-based approach for predicting temporal changes in atherosclerotic plaque. The goal is to distinguish between samples from different classes based on a set of features associated with each sample. Our classifier is being trained to assign each location of the coronary vessel to a class specifying whether and how plaque will change within a certain period of time. The features used to perform the classification are derived from baseline imaging. The classifier is being trained using the information about the

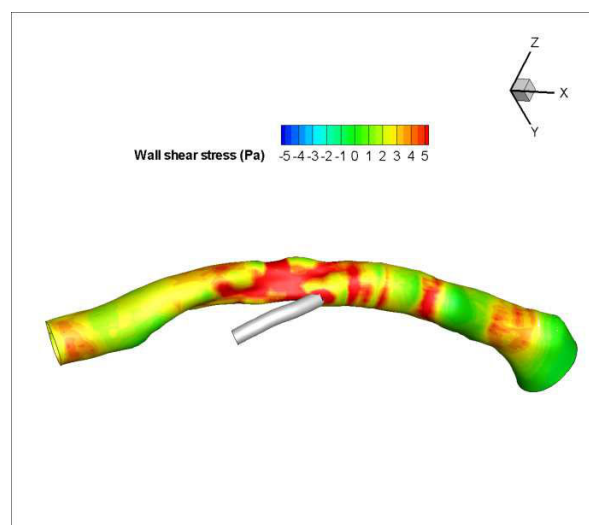


Fig. 4. Example of wall shear stress calculation in the presence of coronary bifurcation.

true classification – in our case information about the plaque status at 12 months derived from the follow-up imaging. The classification process requires registered baseline and 12-month-follow-up in vivo 3-D measurements of coronary arterial morphology, function, hemodynamics, and plaque composition as described above. It also utilizes atherosclerotic biomarkers, information about patient demographics, and information whether or not interventional treatment was applied to a specific location of the vessel wall. Using all these features which are compiled either regionally or segmentally, location-specific multi-factorial feature vectors are constructed for the corresponding baseline and follow-up vessel locations and used for classifier training. The outline of the classifier training is shown in Fig. 5a.

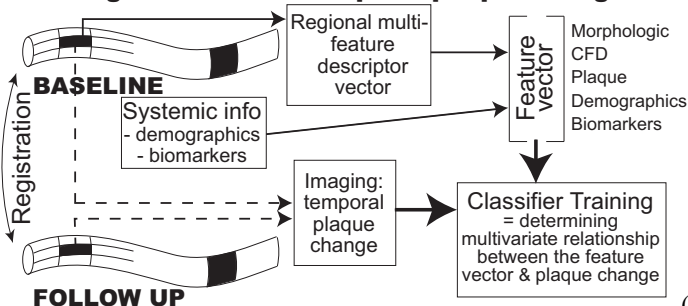
As with any classification based analysis method, the classifiers must allow operation in two basic modes: training and classification. In both modes, the coronary vessels must be segmented and all quantitative indices must be determined to form the regional and/or segmental feature vectors (Table I). When the method operates in the training mode, the computed features are accompanied by follow-up-determined information about the atherosclerosis progression in 12 months (e.g., regression, no change, progression, events, etc.). Using this information, a statistical classifier is trained to predict the disease status and/or events at follow up using the baseline disease descriptors (Fig. 5b). In the classification (prediction, testing) mode, previously unseen coronary vessels are analyzed - segmented, hemodynamic shear stress computed, plaque characterized, biomarkers determined, and the sets of regional or segmental features are presented to the previously trained classifier that classifies each region or segment in one of the available classes – e.g., disease regression, no change, progression, events, etc. that are expected to happen in 12 months from the time of the baseline imaging.

TABLE I

REGIONAL, SEGMENTAL, AND SYSTEMIC FEATURES = PREDICTION SYSTEM INPUT VARIABLES (A REPRESENTATIVE SUBSET).

Regional features	Segmental Features	Systemic Features
Plaque thickness average (PTA) [mm]	Plaque thickness average (PTA) [mm]	Stable disease [Y/N]
Wall shear stress average (WSSA) [dynes/cm ²]	Wall shear stress average (WSSA) [dynes/cm ²]	Age [1]
Wall curvature [°/cm]	Vessel area average [mm ²]	Gender [M/F]
Abs. diff. (PTA – cross-sectional PTA) [mm]	Vessel lumen average [mm ²]	Hypertension [Y/N]
Stdev diff. (PTA – cross-sectional PTA) [1]	Stdev of plaque thickness [1]	Systolic BP [mmHg]
Abs.diff.(WSSA – cross-sect.WSSA) [dynes/cm ²]	Stdev of WSS [dynes/cm ²]	Diastolic BP [mmHg]
Stdev diff. (WSSA – cross-sectional WSSA) [1]	Percent stenosis [%]	Hyperlipidimia [Y/N]
Fibrous plaque volume [mm ³]	Luminal & vessel distensibilities [%]	Smoking [Y/N]
Fibro-fatty plaque volume [mm ³]	Expansive & constrictive remodeling indices [%]	Diabetes [Y/N]
Necrotic core plaque volume [mm ³]	Fibrous plaque volume [mm ³]	Family history CAD [Y/N]
Dense calcific plaque volume [mm ³]	Fibro-fatty plaque volume [mm ³]	Previous MI [Y/N]
Fibrous plaque percentage [%]	Necrotic core plaque volume [mm ³]	Previous angina [Y/N]
Fibro-fatty plaque percentage [%]	Dense calcific plaque volume [mm ³]	Race [C/A/H/P]
Necrotic core plaque percentage [%]	Fibrous plaque percentage [%]	High sensitivity CRP
Dense calcific plaque percentage [%]	Fibro-fatty plaque percentage [%]	Fibrinogen
Fibrous plaque % in plaque cap region [%]	Necrotic core plaque percentage [%]	ICAM-1
Fibro-fatty plaque % in plaque cap region [%]	Dense calcific plaque percentage [%]	MMP-9
Necrotic core plaque % in plaque cap region [%]	Fibrous plaque % in plaque cap region [%]	Homocysteine
Dense calcific plaque % in plaque cap region [%]	Fibro-fatty plaque % in plaque cap region [%]	LDL
	Necrotic core plaque % in plaque cap region [%]	
	Dense calcific plaque % in plaque cap region [%]	

TRAINING of classifier to predict changes in a single variable of temporal plaque change



PREDICTION of plaque changes and performance assessment using a trained classifier

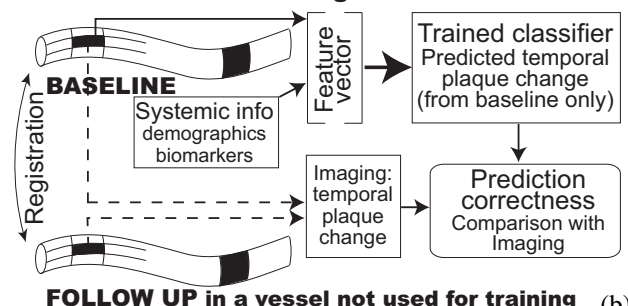


Fig. 5. Outline of classifier training and its use for plaque change prediction. (a) For each outcome variable, each regional location, and N-1 vessels, a classifier is trained using leave-one-vessel-out approach. Example shows training based on regional features, training using segmental features is conceptually identical. (b) The trained classifier predicts the plaque change in 12 months in the vessel that was not used for classifier training. For assessment of the classifier performance, the predicted value is compared with the image-based “truth.” In the leave-one-out paradigm, the classifier training/testing is performed N times with different vessels left out in each run.

IV. CONCLUSION

The above outlined approach allows comprehensive 3-D analysis of coronary morphology, tissue composition, and hemodynamics. Many of the individual modules have already been fully developed and extensively validated. The project is approaching completion with over 40 subject longitudinally imaged at baseline and 12-month. The developed environment allows to routinely obtain all quantitative indices provided in Table I although several batches of blood samples must still be analyzed to provide a complete set of biomarkers. The current focus of our work is on development of the predictive classifier and – finally – assessing its ability to predict coronary plaque progression and its effect on coronary disease status and development.

REFERENCES

- [1] G. P. M. Prause, S. C. DeJong, C. R. McKay, and M. Sonka, “Towards a geometrically correct 3-D reconstruction of tortuous coronary arteries based on biplane angiography and intravascular ultrasound,” *International Journal of Cardiac Imaging*, vol. 13, no. 6, pp. 451–462, Dec. 1997.
- [2] A. Wahle and M. Sonka, “Coronary plaque analysis by multimodality fusion,” in *Plaque Imaging: Pixel to Molecular Level*, ser. Studies in Health, Technology and Informatics, J. S. Suri, C. Yuan, D. L. Wilson, and S. Laxminarayan, Eds., vol. 113. Amsterdam: IOS Press, 2005, pp. 321–359.
- [3] A. Wahle, M. E. Olszewski, and M. Sonka, “Interactive virtual endoscopy in coronary arteries based on multi-modality fusion,” *IEEE Transactions on Medical Imaging — Virtual Endoscopy*, vol. 23, no. 11, pp. 1391–1403, Nov. 2004.
- [4] R. Medina, A. Wahle, M. E. Olszewski, and M. Sonka, “Curvature and torsion estimation for coronary artery motion analysis,” in *Medical Imaging 2004: Physiology, Function, and Structure from Medical Images*, A. A. Amini and A. Manduca, Eds., vol. 5369. Bellingham WA: SPIE Proceedings, 2004, pp. 504–515.