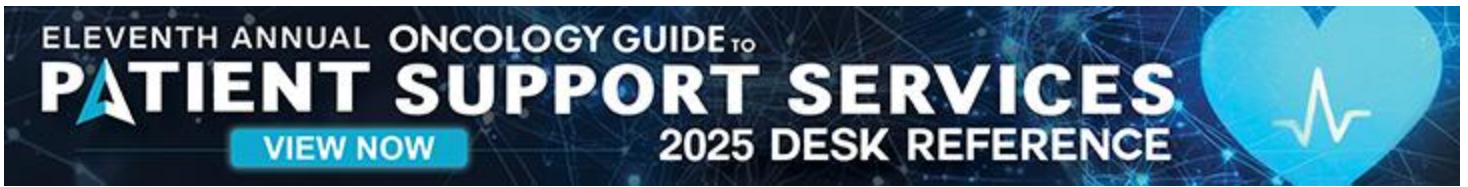

ADVERTISEMENT







FDA Approves First PSMA-Targeted PET Imaging Drug for Prostate Cancer

[FDA APPROVALS, NEWS & UPDATES](#)


[BOOKMARK](#)


[PRINT](#)

- 
- 
- 
- 

On **December 1, 2020**, the FDA approved Gallium 68 PSMA-11 (Ga 68 PSMA-11; University of California), the first drug for positron emission tomography (PET) imaging of prostate-specific membrane antigen (PSMA)-positive lesions in men with prostate cancer. Ga 68 PSMA-11 is indicated for men with suspected metastatic prostate cancer that may be curable by surgery or by radiation, and for suspected recurrent prostate cancer based on elevated serum prostate-specific antigen (PSA) levels.

Ga 68 PSMA-11 is a radioactive drug that is administered via intravenous injection. Ga 68 PSMA-11 binds to PSMA, an important target for prostate cancer imaging.

The approval of Ga 68 PSMA-11 was based on the results of 2 prospective clinical trials in 960 men with prostate cancer who received 1 Ga 68 PSMA-11 with PET and computed tomography or with PET and magnetic resonance imaging. In the first study, 325 patients were candidates for surgery or had an increased risk for metastasis. Among the patients who had surgery, positive readings in the pelvic lymph nodes on Ga 68 PSMA-11 PET had a clinically significant rate of metastatic cancer confirmed by surgical pathology.

The second study included 635 patients with biochemical evidence of recurrent prostate cancer. In all, 74% of the patients had ≥ 1 positive lesions, as detected by Ga 68 PSMA-11 PET in at least 1 body region. Of those with positive Ga 68 PSMA-11 PET readings

and correlative tissue pathology from biopsies, the results from baseline or follow-up imaging by conventional methods, and the serial PSA levels, 91% had confirmed local recurrence or metastasis of prostate cancer.

No serious adverse events were seen with Ga 68 PSMA-11. The most common adverse reactions were nausea, diarrhea, and dizziness. This drug is associated with a risk for misdiagnosis, because Ga 68 PSMA-11 binding may occur in other types of cancer, as well as certain nonmalignant processes.

Related Items

[FDA OKs Penpulimab-kcqx for Non-Keratinizing Nasopharyngeal Carcinoma](#)

[June 2025, Vol 15, No 6](#)

[FDA APPROVALS, NEWS & UPDATES](#)

[FDA Greenlights Nivolumab With Ipilimumab for Unresectable, Metastatic Hepatocellular Carcinoma](#)

[June 2025, Vol 15, No 6](#)

[FDA APPROVALS, NEWS & UPDATES](#)

[FDA Approves Nivolumab With Ipilimumab for Unresectable or Metastatic MSI-H or dMMR Colorectal Cancer](#)

[June 2025, Vol 15, No 6](#)

[FDA APPROVALS, NEWS & UPDATES](#)

[Tislelizumab-jsgr Gets New Indication for First-Line Treatment of Advanced Esophageal Squamous Cell Carcinoma in Combination With Chemotherapy](#)

[June 2025, Vol 15, No 6](#)

[FDA APPROVALS, NEWS & UPDATES](#)

ADVERTISEMENT



ADVERTISEMENT

Educational articles by oncology
healthcare professionals.
Evidence-based data offered with compassion.
Inspiring stories.

Education Throughout the Journey
CONQUER
the journey informed



CLICK HERE to request a complimentary
bulk subscription to distribute to your patients

ADVERTISEMENT

Educational articles by oncology
healthcare professionals.
Evidence-based data offered
with compassion.
Inspiring stories.

Education Throughout
the Journey
CONQUER
the journey informed

>> CLICK HERE to request a
complimentary bulk subscription
to distribute to your patients



[Privacy Policy.](#)

