

# Group Distal Movement of Teeth Using Microscrew Implant Anchorage

Hyo-Sang Park<sup>a</sup>; Soo-Kyung Lee<sup>b</sup>; Oh-Won Kwon<sup>c</sup>

**Abstract:** The purpose of this study was to quantify the treatment effects of distalization of the maxillary and mandibular molars using microscrew implants. The success rate and clinical considerations in the use of the microscrew implants were also evaluated. Thirteen patients who had undergone distalization of the posterior teeth using forces applied against microscrew implants were selected. Among them, 11 patients had mandibular microscrew implants and four patients had maxillary implants, including two patients who had both maxillary and mandibular ones at the same time. The maxillary first premolar and first molars showed significant distal movement, with no significant distal movement of the anterior teeth. The mandibular first premolar and first and second molars showed significant distal movement, but no significant movement of the mandibular incisor was observed. The microscrew implant success rate was 90% over a mean application period of  $12.3 \pm 5.7$  months. The results might support the use of the microscrew implants as an anchorage for group distal movement of the teeth. (*Angle Orthod* 2005;75:602–609.)

**Key Words:** Microscrew implants; Anchorage; Group distalization

## INTRODUCTION

During the past two decades, the use of nonextraction treatment has increased, and many methods of distalization of the maxillary molars have been developed and used.<sup>1–8</sup> Distalization appliances except for extraoral appliances always develop reciprocal, adverse side effects. The anterior teeth tend to move forward during distalization of the molars and need to be retracted against the distalized molars later. The forward movement of the distalized molars during anterior tooth retraction often offsets the treatment effect of the distalization appliances.<sup>4</sup> Furthermore, the treatment time is prolonged.

When managing low-angle patients with crowding in

the mandibular arch, the extraction of teeth might be considered, but extraction may deepen the anterior overbite and make treatment more difficult. Alignment of the teeth without extractions may flare the incisors and deleteriously affect the facial profile. To minimize these problems, the mandibular molars should be distalized. However, there have not been many studies of mandibular molar distalization except for lip bumper investigations. The lip bumper was shown to not only distalize the molars but also to procline the incisors.<sup>9,10</sup>

With the use of dental implants,<sup>11</sup> miniplates,<sup>12</sup> and screws<sup>13–15</sup> as anchorage, the distal movement of the anterior teeth or posterior teeth (or both) without anchorage loss has become possible.<sup>15–17</sup> Among these devices, the microscrew implants have the advantages of easy placement and removal, with minimal anatomical limitations because of their small size and low cost.<sup>15</sup> Therefore, their clinical applications have been expanded, and they have been adopted for distalization of the mandibular molars. The nature of absolute anchorage allows for retraction of the anterior teeth with simultaneous distal movement of the posterior teeth. However, the treatment effects of the microscrew implants have not been quantified.

The purpose of this study was to quantify the treatment effects of the microscrew implants on distalization of the maxillary and mandibular molars. The success rate and clinical consideration of the microscrew implants will also be discussed.

<sup>a</sup> Associate Professor, Department of Orthodontics, College of Dentistry, Kyungpook National University, Jung-Gu, Daegu, Korea.

<sup>b</sup> Postgraduate student, Department of Orthodontics, College of Dentistry, Kyungpook National University, Jung-Gu, Daegu, Korea.

<sup>c</sup> Professor, Department of Orthodontics, College of Dentistry, Kyungpook National University, Jung-Gu, Daegu, Korea.

Corresponding author: Hyo-sang Park, DDS, MSD, PhD, Department of Orthodontics, College of Dentistry, Kyungpook National University, 101, Dongin-2-Ga, Jung-Gu, Daegu 700-422, Korea (e-mail: parkhs@knu.ac.kr).

Accepted: June 2004. Submitted: April 2004.

© 2005 by The EH Angle Education and Research Foundation, Inc.

**TABLE 1.** The Descriptive Distribution of the Patients

Patient's Sex	Age	Brand and Type of Microscrew φ = diameter	Location of Microscrew Placement	Duration of Force Application	Failure (Months After Placement)	Replacement (Location, Period of Use)	Pericoronitis on Lower Second Molar
Kim SM (female)	11 y	Dentos	#37 DB	2 mo	Y (2 mo)	Y (#36-37, 7 mo)	Operculum
		An 12-204	#47 DB	9 mo	N		Operculum
Lee SE (female)	14 y	Dentos	#36-37 B	8 mo	N		
		Ax 12-108	#46-47 B	8 mo	N		
Lee DH (male)	13 y 9 mo	Osteomed	#15-16 B	17 mo	N		
		(1.2φ, 6 mm)	#25-26 B	17 mo	N		
		Dentos	#37 DB	17 mo	N		
		An 12-204	#47 DB	17 mo	N		
Sohn HA (female)	13 y 6 mo	Osteomed	#37 DB	13 mo	N		Mild
		(1.2φ, 6 mm)	#47 DB	7 mo	Y (7 mo)	Y (#37, 6 mo)	Mild
Kim DH (male)	13 y 4 mo	Osteomed	Lt. R	10 mo	N		
		(1.2φ, 6 mm)	Rt. R	2 mo	Y (2 mo)	Y (#46-47, 7 mo)	
Kang SJ (female)	15 y 3 mo	Osteomed	#37 DB	16 mo	N		
		(1.2φ, 6 mm)	#47 DB	16 mo	N		
NA JH (female)	16 y 11 mo	Osteomed	#37 DB	6 mo	N		
		(1.2φ, 6 mm)	#47 DB	6 mo	N		
Choi JH (female)	28 y 3 mo	Osteomed	#37 DB	9.2 mo	N		
		(1.2φ, 10 mm)	#47 DB	9.2 mo	N		
		Osteomed	#16-17P	9.2 mo	N		
		(1.2φ, 6 mm)	#26-27P	9.2 mo	N		
Kwon SC (male)	23 y 3 mo	Osteomed	#37 DB	21 mo	N		
		(1.2φ, 6 mm)	#47 DB	21 mo	N		
Kim KI (female)	22 y 5 mo	Osteomed	#37 DB	13 mo	N		
		(1.2φ, 8 mm)	#47 DB	13 mo	N		
Lim SJ (male)	22 y 6 mo	Martin	Rt. R	22 mo	N		
		(2.0φ, 15 mm)	Lt. R	21 mo	N		
Lee SK (male)	12 y 8 mo	Osteomed	#15-16 B	18 mo	N		
		(1.2φ, 8 mm)	#25-26 B	18 mo	N		
Park JM (female)	25 y 7 mo	Osteomed	#15-16 B	7 mo	N		
		(1.2φ, 8 mm)	#25-26 B	7 mo	N		

Lt. R, left retromolar area; Rt. R, right retromolar area; DB, distobuccal alveolar bone; B, buccal alveolar bone; P, palatal alveolar bone; Y, yes; N, no.

## MATERIALS AND METHODS

The cephalometric radiographs and dental casts of 13 consecutive patients who had undergone orthodontic treatment at the Dental Department of the University Medical Center and had been treated with nonextraction treatment (except for one patient who had been treated with maxillary first premolar extraction and distalization of the mandibular teeth) were used. Eleven patients had mandibular microscrew implants to distalize the whole mandibular dentition. Four patients had maxillary microscrew implants, whereas two of these four patients had mandibular implants at the same time (Table 1). All patients were treated by one clinician. The mean age of the patients was  $17.9 \pm 5.7$  years (maximum: 28 years three months; minimum: 11 years).

### Appliances

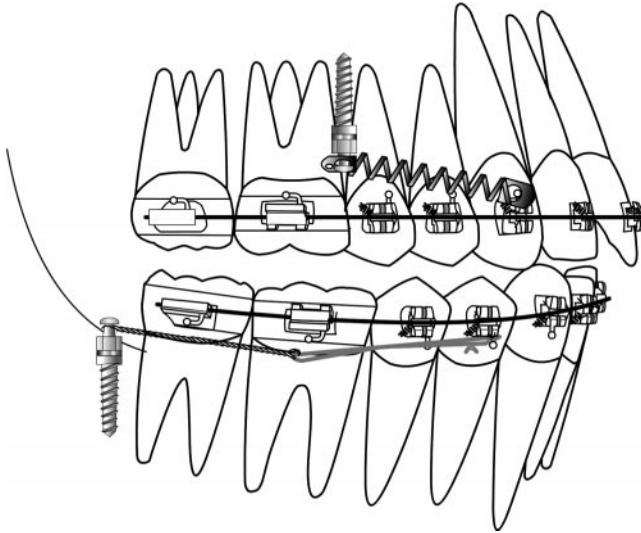
Slot straight wire brackets (0.022 inch) were used in all patients, and distalizing forces of approximate 200 g were applied from the maxillary and mandibular mi-

cro-screw implants to the canines or premolars by means of NiTi closing coil springs in the maxillary arch and elastomeric threads (Super thread® RMO, Denver, Colo) in the mandibular arch (Figure 1). The archwires used during distalization were 0.016 × 0.022-inch TMA or stainless steel in the maxillary arch and 0.018 × 0.025-inch TMA or stainless steel in the mandibular arch. The detailed treatment procedures have been well described in previous reports.<sup>17</sup> The directions of the applied forces were backward and upward in the maxillary arch and backward and downward in the mandibular arch (Figure 1).

### Screw implants

The screw implants used in this study were two miniscrews from Martin (Kalamazoo, Mo), 22 microscrews from Osteomed Co (Dallas, Tex), and six microscrew implants from Dentos (Daegu City, Korea) (Table 1).

In the maxilla, four microscrew implants were placed in the buccal alveolar bone between the second pre-



**FIGURE 1.** A distalizing force was applied to a canine by a NiTi coil spring connected from a maxillary microscrew implant, which was placed into alveolar bone between a second premolar and a first molar. A distalizing force was applied from the microscrew implant to the mandibular canine.

molars and first molars and two in the palatal alveolar bone between the first and second molars. Sixteen microscrew implants were placed in the bone distal to mandibular second molars, two microscrews and two miniscrews in the retromolar area, and two micro-

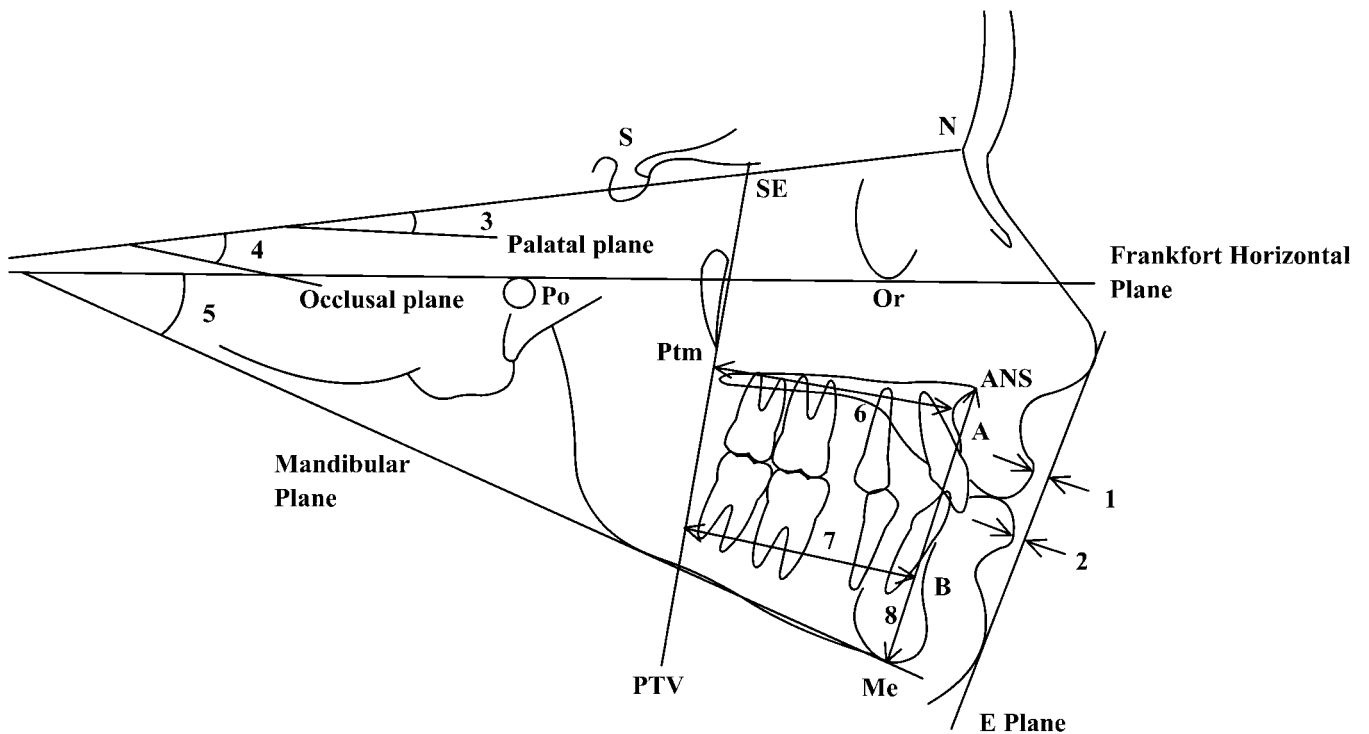
screws in the alveolar bone between the mandibular first and second molars.

The surgical procedure included incision of the overlying mucosa, preparing a hole with a pilot drill under coolant irrigation, and placement of microscrew implants with a screwdriver. The detailed procedure has been described in earlier reports.<sup>14-17</sup> A ligature wire extension was made to connect the elastic materials to the screw implants, which were placed into the bone distal to the mandibular second molars or into the retromolar area because the head of the screw implants tended not to be exposed out of the soft tissue.

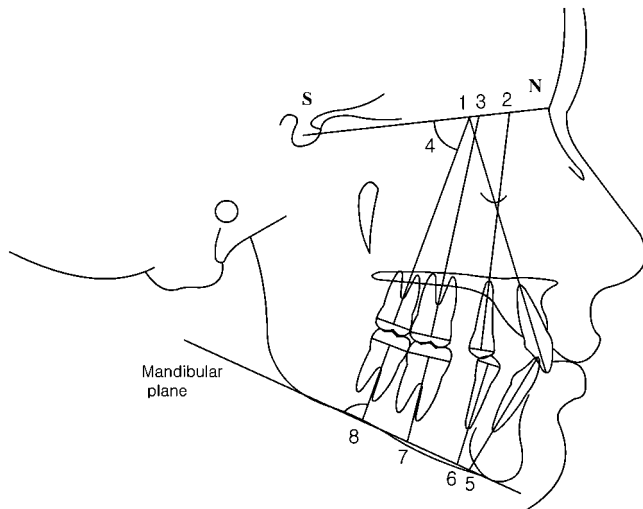
**Cephalometric variables and analysis**

Pretreatment cephalometric radiographs were collected. Pretreatment cephalograms were used if there was no more than a three-month difference between the start of treatment and distalization of the teeth. After-treatment cephalograms were collected on all patients. The soft tissue and skeletal measurements, dental angular measurements, and dental linear measurements are illustrated in Figures 2 through 4.

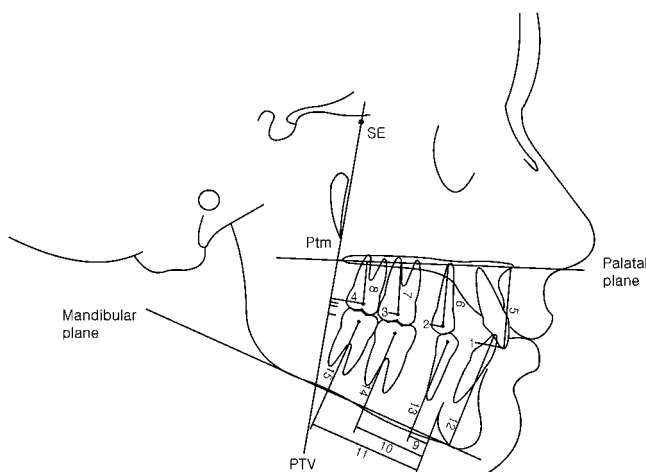
When a double image was present, the midpoint between two points was traced. The measurement point for soft tissue, skeletal, and the maxillary dental linear and angular measurements were the same as reported by Ghosh and Nanda.<sup>4</sup> The centroid point, the mid-



**FIGURE 2.** Cephalometric measurements used in this study. 1. Maxillary lip to E-line; 2. mandibular lip to E-line; 3.  $\angle$ SN-PP (SN-palatal plane angle); 4.  $\angle$ SN-OP (SN-bisected occlusal plane angle); 5.  $\angle$ FMA (Frankfort-mandibular plane angle); 6. PTV to A; 7. PTV to B; 8. ANS to menton.



**FIGURE 3.** Cephalometric dental angular measurements. In maxilla: 1. SN-incisor; 2. SN-first premolar; 3. SN-first molar; 4. SN-second molar. In mandible: 5. MP-incisor; 6. MP-first premolar; 7. MP-first molar; 8. MP-second molar.



**FIGURE 4.** Cephalometric dental linear measurements. Horizontal measurements in maxilla: 1. PTV-incisor tip; 2. PTV-first premolar centroid; 3. PTV-first molar centroid; 4. PTV-second molar centroid. Vertical measurements in maxilla; 5. PP (palatal plane)-incisor; 6. PP-first premolar centroid; 7. PP-first molar centroid; 8. PP-second molar centroid. Horizontal measurements in mandible; 9. MLC (mandibular lingual cortex)-first premolar centroid; 10. MLC-first molar centroid; 11. MLC-second molar centroid. Vertical measurements in mandible; 12. MP-incisor; 13. MP-first premolar centroid; 14. MP-first molar centroid; 15. MP-second molar centroid.

point on a horizontal line between greatest mesial and distal convexity of the crowns, was used for dental linear measurement. To determine the amount of horizontal movement of maxillary teeth, the pterygoid vertical plane (PTV)<sup>18</sup> was used. The vertical movement of the maxillary teeth was determined from superimposition on the palatal plane (PP). The horizontal movement of the mandibular teeth was determined by measuring and comparing the distance from the cen-

triod point of teeth to the mandibular lingual cortex (MLC), whereas the vertical measurements were determined from superimposition on the mandibular plane (MP).

Angular changes of tooth position were determined by inclination of the long axes of the teeth to the sella-nasion plane (SN) in the maxillary arch and to the mandibular plane (MP) in the mandibular arch.

### Dental cast analysis

Arch length discrepancies and intermolar width of the maxillary and mandibular arches were measured before treatment or before distalization and posttreatment.

### Statistical analysis

Descriptive statistics including mean and standard deviation were calculated for 20 cephalometric measurements at pretreatment or before distalization, posttreatment and changes between pre- and posttreatment.

For paired data, a paired *t*-test and a Wilcoxon signed rank test were performed. When the significant measurements were identical in both methods, the *P* values of the paired *t*-test were illustrated, unless the *P* values of both methods were illustrated.

To calculate the error of measurements, all cephalometric films and models were retraced and redigitized and remeasured at a one-month interval. Measurement errors were calculated based on the differences between the first and second measured values with a paired *t*-test. There was no significant difference between the two measurements.

## RESULTS

The descriptive statistics, including the means and standard deviations before distalization, posttreatment, and changes during the treatment interval (before distalization to posttreatment), as measured from the cephalometric radiographs are summarized in Tables 2 and 3.

### Stability of screw implants

The success rate was 90% (27 of 30 screw implants were maintained during force application). The mean period of time of force application was  $12.3 \pm 5.7$  months. Among three failed microscrews, two were on the right and one on the left. The distalization of the teeth was continued by placing three new screw implants into different, but adjacent, locations.

Soft-tissue problems around the screw implants and distal to the second molars (for instance, overgrowing of soft tissue over the second molars) were noted in

**TABLE 2.** Descriptive Statistics of Cephalometric Measurements at Pretreatment, Posttreatment, and Pre- to Posttreatment in a Group in Which the Maxillary Molars Were Distalized ( $n = 4$ )

Measurements	Before Distalization		Posttreatment		Before Distalization to Posttreatment		Significance	
	Mean	SD	Mean	SD	Mean	SD	<i>t</i>	<i>W</i>
Soft tissue								
Upper lip to E-line (mm)	-0.61	2.63	-2.65	1.55	-2.04	1.83	.133	.068
Lower lip to E-line (mm)	0.70	2.08	-0.16	1.76	-0.86	2.17	.647	.715
Skeletal								
SN-PP	8.75	3.43	9.75	3.77	1.00	0.41	.608	.581
SN-Occ	20.25	6.74	21.63	8.29	1.38	1.89	.241	.180
FH-Mn	29.75	9.06	29.63	10.64	-0.13	1.97	.878	.713
PTV-A	51.35	2.90	51.69	1.69	0.34	2.38	.046*	.068
PTV-B	53.80	5.70	54.24	6.90	0.45	2.38	.875	.715
ANS-Me	78.46	8.41	79.45	9.09	0.99	2.27	.591	.465
Dental-angular (°)								
SN-U1	107.75	14.66	104.63	14.31	-3.13	4.27	.290	.141
SN-U4	74.00	5.10	73.94	10.11	-0.06	5.31	.720	.715
SN-U6	65.00	6.48	64.69	6.96	-0.31	4.13	.728	1.00
SN-U7	60.63	8.84	58.56	12.76	-2.06	13.21	.449	.465
Dental-linear (mm)								
PTV-U1	63.20	4.62	62.35	6.03	-0.85	1.99	.240	.465
PTV-U4	42.67	4.82	41.47	6.32	-1.20	2.94	.036*	.068
PTV-U6	27.33	1.52	25.69	1.94	-1.64	1.22	.022*	.068
PTV-U7	15.75	2.29	14.25	1.87	-1.50	1.78	.063	.068
PP-U1	33.50	4.56	33.33	3.92	-0.17	0.86	.875	1.00
PP-U4	26.77	2.89	25.83	3.13	-0.94	1.05	.087	.068
PP-U6	22.90	1.43	22.30	2.74	-0.60	1.37	.412	.465
PP-U7	18.90	2.63	18.75	2.84	-0.15	2.93	.594	.715

\*  $P < .05$ .

two patients. No screw implants showed obvious inflammation.

### Changes of maxillary tooth position

There was a statistically significant difference between the position of the maxillary first premolars and first molars, ie, the teeth were distalized. In addition, there was no reciprocal side effect on the maxillary anterior teeth, as is normally expected when using molar distalizing appliances. Conversely, not only the posterior teeth but also the anterior teeth showed distal tipping, although it was not statistically significant. All maxillary teeth showed intrusion during distalization, even though it was not statistically significant (Table 2).

The transverse dimensional changes as measured from dental casts are shown in Table 4. There was no significant change before and after distalization.

### Changes of mandibular tooth position

The primary treatment effects of mandibular micro-screw implants on the mandibular dentition consisted of a distal tipping movement of the mandibular posterior teeth concurrent with uprighting and distal move-

ment of the mandibular anterior teeth. The mandibular first premolars showed extrusion during distal movement, which positively affected the leveling of the curve of Spee (Table 3).

### Changes in dental arch width

There were no significant differences in maxillary and mandibular intermolar width before and after distalization (Table 4).

## DISCUSSION

The procedure reported in this study was slower than other published distalization methods.<sup>19,20</sup>

However, the overall treatment time would be similar or shorter because all the posterior teeth were retracted simultaneously with microscrew implant-aided mechanics. The anterior teeth were retracted after distalization of the molars in other distalization methods. The separate step-by-step movement of anterior and posterior teeth prolonged the treatment time.

Intraoral distalizing appliances cause an adverse, reciprocal mesial movement of the anterior teeth and premolars during distal movement of the molars. This adverse forward movement of anterior teeth is inevi-

**TABLE 3.** Descriptive Statistics of Cephalometric Measurements at Pretreatment, Posttreatment, and Pre- to Posttreatment in a Group in Which the Mandibular Molars Were Distalized ( $n = 11$ )

Measurements	Before Distalization		Posttreatment		Before Distalization to Posttreatment		Significance
	Mean	SD	Mean	SD	Mean	SD	
Soft tissue							
Upper lip to E-line (mm)	-1.74	1.43	-2.02	2.04	-0.28	1.91	.634
Lower lip to E-line (mm)	0.94	3.17	-0.15	2.19	-1.09	1.77	.068
Skeletal							
SN-PP	9.39	2.41	9.55	2.25	0.16	1.44	.722
SN-Occ	21.50	4.25	19.73	6.18	-1.77	3.26	.101
FH-Mn	28.23	4.11	28.57	4.23	0.34	1.51	.471
PTV-A	50.51	4.05	50.65	4.01	0.15	1.55	.762
PTV-B	54.49	9.86	54.31	9.16	-0.18	3.40	.865
ANS-Me	75.60	5.81	77.48	6.67	1.88	1.64	.003**
Dental-angular (°)							
MP-L1	91.00	6.94	90.20	7.92	-0.80	5.42	.975
MP-L4	80.36	4.00	76.64	7.57	-3.73	6.51	.087
MP-L6	78.80	5.29	73.84	4.40	-4.95	5.94	.020*
MP-L7	85.09	8.85	76.48	6.94	-8.61	6.39	.001**
Dental-linear (mm)							
LC-L4	6.26	3.10	9.22	3.64	2.96	1.83	.0003**
LC-L6	23.74	3.38	26.66	3.44	2.92	2.11	.0009**
LC-L7	35.21	4.61	39.36	5.20	4.15	4.96	.019
MP-L1	45.05	3.71	45.74	3.75	0.69	2.14	.310
MP-L4	36.80	3.34	38.03	3.77	1.23	1.75	.042*
MP-L6	32.80	3.32	33.03	3.22	0.23	1.22	.541
MP-L7	30.57	3.47	29.94	2.79	-0.62	1.93	.310

\*  $P < .05$ ; \*\*  $P < .01$ .**TABLE 4.** Changes in Intermolar Width and Arch Length Discrepancy

	Pretreatment		Posttreatment		Significance	
	Mean	SD	Mean	SD	<i>t</i>	<i>W</i>
Upper intermolar width (mm)	41.88	2.66	41.69	2.42	.7601	.676
Lower intermolar width (mm)	42.17	3.14	42.56	3.60	.7109	.625
Arch length discrepancy	5.9	1.41	0	0	.000	.000

table using an intraoral molar distalization appliance. The forward moved position of the anterior teeth should be retracted back after creating space with the distal movement of the molars and premolars. During this anterior tooth retraction, the posterior teeth are used as anchorage so that the distalized molars are moved forward, which offsets the efficiency of distalization.<sup>4</sup> Moreover, the overall movement of the anterior teeth is a round-trip movement.

On the other hand, distal movement using micro-screw implants is a group movement of buccal segment teeth. There is no forward movement of the anterior teeth in micro-screw implant-aided mechanics. Therefore, these procedures did not produce any adverse side effect on the anterior teeth. In fact, there is no force to move anterior teeth forward, and therefore there is no round-trip movement of teeth. Instead, the

anterior teeth were distalized during distalization of the molars.

The maxillary incisors, premolars, and molars moved distally, with statistical significance present in the first premolar and first molar values. In the maxillary distalization sample, all teeth showed distal tipping, with more distal tipping on the second molars than on the first molar and first premolar. This could be explained by the middle teeth moving more bodily because the tooth distal to middle teeth might prevent the distal tipping. The same phenomenon was evident in the mandibular arch.

In the maxillary arch, the posterior teeth were intruded during distal movement probably because of the vertical component of force exerted from the micro-screw implants. However, the mandibular teeth showed extrusion during distalization. Because of the

small sample size, statistical significance was not obtained in several measurements, even though there seemed to be a tendency toward distal tipping. Therefore, a study using a larger sample is necessary.

Distalization appliances tend to open the mandibular plane by moving the molars distally, thus creating a wedging effect. However, distalization with screw implants did not open the mandibular plane; rather, it closed the mandibular plane. The intrusive component of force might prevent the opening of the mandibular plane. The intrusive component of applied force can be determined by the vertical position of the micro-screw implant head, where the elastic material is connected. Regarding the intrusion of molars, Umemori et al<sup>12</sup> noted that, after treatment of open bite, correction showed relapse after molar intrusion. Their sample was open-bite cases, which were treated by intrusion and distalization of the molars, and the vertical dimension was decreased with treatment. This may change the length of masticatory muscle fibers and induce relapse. On the other hand, the intrusive movement in these mechanics does not decrease or increase vertical dimension but rather maintains the vertical dimension. This would result in better retention.

The mini- or microscrew implants withstood 200 g of force throughout treatment except for three microscrew implants, which were replaced, and distalization was continued. Most screw implants provided stable anchorage. The success rate of the screw implants was 90%. Because of their small size, microscrew implants can be replaced easily. When considering replacement of screw implants, the success rate might be 100%.

Miyawaki et al<sup>21</sup> stated that microscrews less than one mm in diameter showed 0% success (0 out of 10) and 1.5-mm-diameter screws and two-mm miniscrews had 83.9% and 85% success rates, respectively. However, a previous study<sup>22</sup> reported 93.3% success rate after a mean of 15.6 months of force application for six 2.0-mm-diameter miniscrews and 174 1.2-mm-diameter microscrews, placed in 72 patients. The success rate of these two studies showed a significant difference. A well-designed study using a large sample is needed to elucidate factors that may affect success of screw implants.

The distal movement of mandibular posterior teeth may produce pericoronitis by the accumulation of soft tissue over the crown of the second molar. To prevent this, the available space distal to molar should be checked when setting up a treatment plan. When the maxillary second molars are out of the line of occlusion, distalization must be avoided. There was no discernible detrimental change in the roots of teeth where the microscrew implant was placed. No pain or discomfort was reported by the patients.

The force used in this study was less than 200 g. The reason for using a low force was to increase the stability of the screw implants. After assessing the stability of the screw by checking mobility, the force can be increased. The increased level of force may affect the tooth movement rate positively. Mobility of the screw might be a crucial factor of failure (in preparation). The absence of mobility indicates osseointegration of implant bodies to the bone. After achieving osseointegration, the orthodontic force can be increased without harmful effect on the stability of the screw implants.

The approximate 200 g of force on each side can be roughly calculated about 30 g per tooth, which is very light when compared with ordinary orthodontic forces. Slow movement with light force may be more physiologic when compared with fast tooth movement.

## CONCLUSIONS

The microscrew implants placed in the maxillary interradicular bone and mandibular retromolar area provided absolute anchorage for the en masse distal movement of posterior teeth. By moving posterior teeth simultaneously, the treatment time may be shortened and round tripping of the anterior teeth can be avoided. The success rate for the microscrew implants was 90%.

## REFERENCES

1. Melsen B. Effects of cervical anchorage during and after treatment: an implant study. *Am J Orthod.* 1978;73:526–540.
2. Cope JB, Buschang PH, Cope DD, Parker J, Blackwood HO III. Quantitative evaluation of craniofacial changes with Jasper jumper therapy. *Angle Orthod.* 1994;64:113–122.
3. Ngantung V, Nanda RS, Bowman SJ. Posttreatment evaluation of the distal jet appliance. *Am J Orthod Dentofacial Orthop.* 2001;120:178–185.
4. Ghosh J, Nanda RS. Evaluation of an intraoral maxillary molar distalization technique. *Am J Orthod Dentofacial Orthop.* 1996;110:639–646.
5. Bussick T, McNamara JA. Dentoalveolar and skeletal changes associated with the pendulum appliance. *Am J Orthod Dentofacial Orthop.* 2000;117:333–343.
6. Cetlin NM, Ten Hoeve A. Nonextraction treatment. *J Clin Orthod.* 1983;17:396–413.
7. Runge ME, Martin JT, Bukai F. Analysis of rapid maxillary molar distal movement without patient cooperation. *Am J Orthod Dentofacial Orthop.* 1999;115:153–157.
8. Bolla E, Muratore F, Carano A, Bowman SJ. Evaluation of maxillary distalization with the distal jet: a comparison with other contemporary methods. *Angle Orthod.* 2002;72:481–494.
9. Drmeddent AK, Nanda RS, Ghosh J. Muscle activity with the mandibular lip bumper. *Am J Orthod Dentofacial Orthop.* 2000;117:384–390.

10. Murphy CC, Magness WB, English JD, Fraizier-Bowers SA, Salas AM. A longitudinal study of incremental expansion using a mandibular lip bumper. *Angle Orthod.* 2003;73:396–400.
11. Roberts WE, Nelsen CL, Goodacre CJ. Rigid implant anchorage to close a mandibular first molar extraction site. *J Clin Orthod.* 1994;38:693–704.
12. Umemori M, Sugawara J, Mitani H, Nagasaka H, Kawamura H. Skeletal anchorage system for open bite correction. *Am J Orthod Dentofacial Orthop.* 1999;115:166–174.
13. Creekmore TD, Eklund MK. The possibility of skeletal anchorage. *J Clin Orthod.* 1983;17:266–269.
14. Park HS. The skeletal cortical anchorage using titanium micro-screw implants. *Korean J Orthod.* 1999;29:699–706.
15. Park HS. *The Use of Micro-Implant as Orthodontic Anchorage.* Seoul: Nare Pub Co; 2001:5–192.
16. Park HS, Bae SM, Kyung HM, Sung JH. Micro-implant anchorage for treatment of skeletal Class I bialveolar protrusion. *J Clin Orthod.* 2001;35:417–422.
17. Park HS, Kwon DG, Sung JH. Nonextraction treatment with micro-screw implant. *Angle Orthod.* 2004;74:539–549.
18. Enlow DH, Kuroda T, Lewis AB. The morphological and morphogenetic basis for craniofacial form and pattern. *Angle Orthod.* 1971;41:161–168.
19. Muse DS, Fillman MJ, Emmerson WJ, Mitchell RD. Molar and incisor changes with Wilson rapid molar distalization. *Am J Orthod Dentofacial Orthop.* 1993;104:556–565.
20. Gianelly AA, Vaitas AS, Thomas WM. The use of magnets to move molars distally. *Am J Orthod Dentofacial Orthop.* 1989;96:161–167.
21. Miyawaki S, Koyama I, Inoue M, Mishima K, Sugahara T, Takano-Yamamoto T. Factors associated with the stability of titanium screws placed in the posterior region for orthodontic anchorage. *Am J Orthod Dentofacial Orthop.* 2003;124:373–378.
22. Park HS. Clinical study on success rate of micro-screw implants for orthodontic anchorage. *Korean J Orthod.* 2003;33:151–156.